Cardiac Electrophysiology Case Based Learning

Arrhythmia monitoring and update on new technologies

Joshua Silverstein, MD

2/26/18 Licking Memorial CME Conference

Disclosures

- Consulting and Education – Biosense Webster
- Consulting - Medtronic

Objectives

- Arrhythmia Monitoring
  - Holter
  - Event monitor
  - Home Telemetry
  - Loop Recorder
  - smartphone app
- Discuss New Pacing Technologies
  - Leadless pacing
  - His Bundle Pacing
- Reducing stroke risk in patients that cannot take oral anticoagulants who are at high risk for stroke

Case 1:

- A 56 yo woman with longstanding history of palpitations c/o worsening palpitations for the past three months. The palpitations happen on a daily basis and last most of the day. On ECG, she is found to have ventricular bigeminy. What arrhythmia monitoring would you recommend?
  - A) Event Monitor/Home Telemetry
  - B) Holter Monitor
  - C) Loop Recorder
  - D) Smartphone App

Case 2:

- A 32 yo gentleman with no prior cardiac history complains of palpitations that occur about once a week, are sudden in onset and offset, and last for 1-2 minutes. The episodes are associated with shortness of breath and near-syncope. Which heart monitor would you recommend?
  - A) Event Monitor/Home Telemetry
  - B) Holter Monitor
  - C) Loop Recorder
  - D) Smartphone App

Case 3:

- A 75 year old gentleman with history of diabetes, htn, CAD s/p CABG, and paroxysmal afib managed with sotalol c/o intermittent palpitations that occur every few weeks. What heart monitor would you recommend?
  - A) Event Monitor/Home Telemetry
  - B) Holter Monitor
  - C) Loop Recorder
  - D) Smartphone App

Case 4:

- A 65 year old woman with history of obesity, OSA, and right bundle branch block presents to the ER after her third syncopal episode in the last 5 years. The episodes are sudden in onset and offset and have no warning. She is not orthostatic and there is no clear cause of her syncope. What arrhythmia monitor would you recommend?
  - A) Event Monitor/Home Telemetry
  - B) Holter Monitor
  - C) Loop Recorder
  - D) Smartphone App

Holter Monitor

- Continuous recording of every heart beat over a specified amount of time.
- Typically monitor for 1-5 days.
- Only helpful to detect arrhythmias over a short period of time.
- Useful to quantitate amount of PVCs or PACs over a period of time.

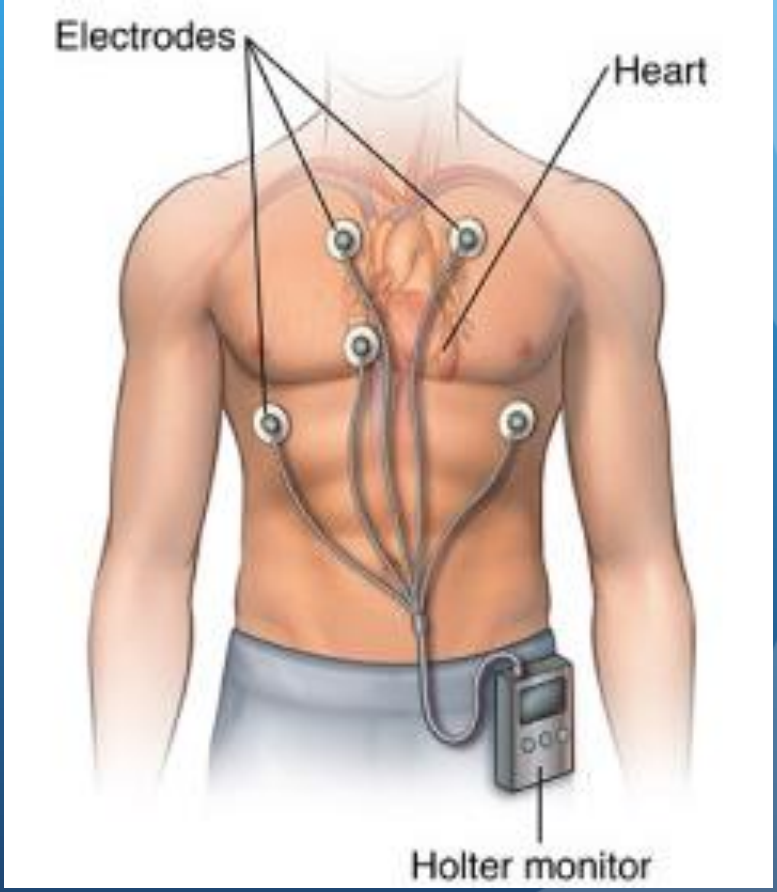

Event Monitor/Home Telemetry

- Event monitors typically record when triggered by the patient or when prespecified criteria are met (i.e. heart rate above or below a threshold, pauses, wide complex tachycardia).
- Home telemetry is like extended Holter monitor (typically over 30 days). Difference is that the rhythm is being watched at a monitoring center real-time.

Loop Recorder

- Works like an extended event monitor. Records rhythm when triggered by patient or when prespecified criteria are met (bradycardia, tachy, pauses).
- Not monitored real-time, but transmissions can be sent in remotely.
- Useful for long-term rhythm monitoring (lasts 2-3 yrs), or for infrequent events.
- Also useful for people who are allergic to adhesive.



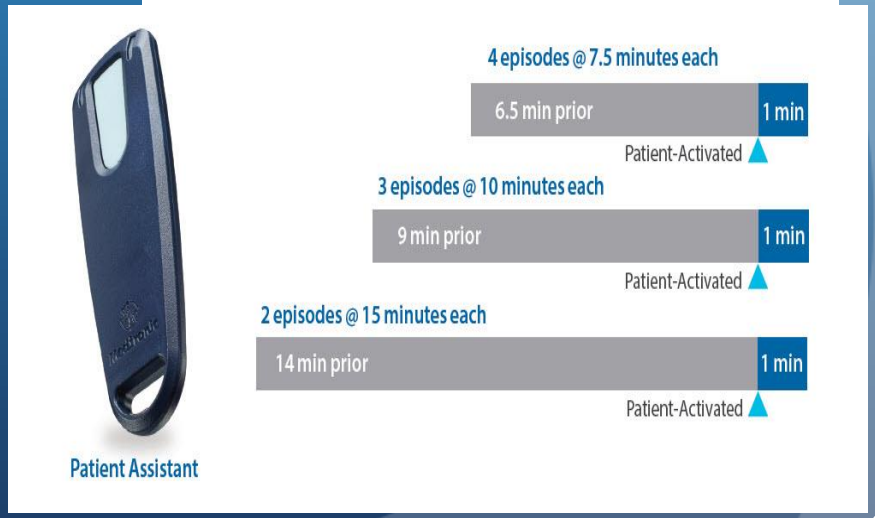

Smartphone Arrhythmia Monitoring

- Patient needs to have a smart phone.
- Good for symptomatic palpitations that last long enough to be able to get the electrodes out and record arrhythmia.
- Arrhythmia can be stored in phone and emailed to provider.

Case 1:

- A 56 yo woman with longstanding history of palpitations c/o worsening palpitations for the past three months. The palpitations happen on a daily basis and last most of the day. On ECG, she is found to have ventricular bigeminy. What arrhythmia monitoring would you recommend?
  - A) Event Monitor/Home Telemetry
  - B) Holter Monitor
  - C) Loop Recorder
  - D) Smartphone App

Case 2:

- A 32 yo gentleman with no prior cardiac history complains of palpitations that occur about once a week, are sudden in onset and offset, and last for 1-2 minutes. The episodes are associated with shortness of breath and near-syncope. Which heart monitor would you recommend?
  - A) Event Monitor/Home Telemetry
  - B) Holter Monitor
  - C) Loop Recorder
  - D) Smartphone App

Case 3:

- A 75 year old gentleman with history of diabetes, htn, CAD s/p CABG, and paroxysmal afib managed with sotalol c/o intermittent palpitations that occur every few weeks. What heart monitor would you recommend?
  - A) Event Monitor/Home Telemetry
  - B) Holter Monitor
  - C) Loop Recorder
  - D) Smartphone App

Case 4:

- A 65 year old woman with history of obesity, OSA, and right bundle branch block presents to the ER after her third syncopal episode in the last 5 years. The episodes are sudden in onset and offset and have no warning. She is not orthostatic and there is no clear cause of her syncope. What arrhythmia monitor would you recommend?
  - A) Event Monitor/Home Telemetry
  - B) Holter Monitor
  - C) Loop Recorder
  - D) Smartphone App

Case 5: Weakness and Fatigue

- A 68 year old woman with history of morbid obesity, ESRD on peritoneal dialysis, diabetes, htn, hlp, and obstructive sleep apnea presents to the ER with several weeks of increasing shortness of breath, weakness, and fatigue.
- She is found to have the following ECG:

12 lead ECG

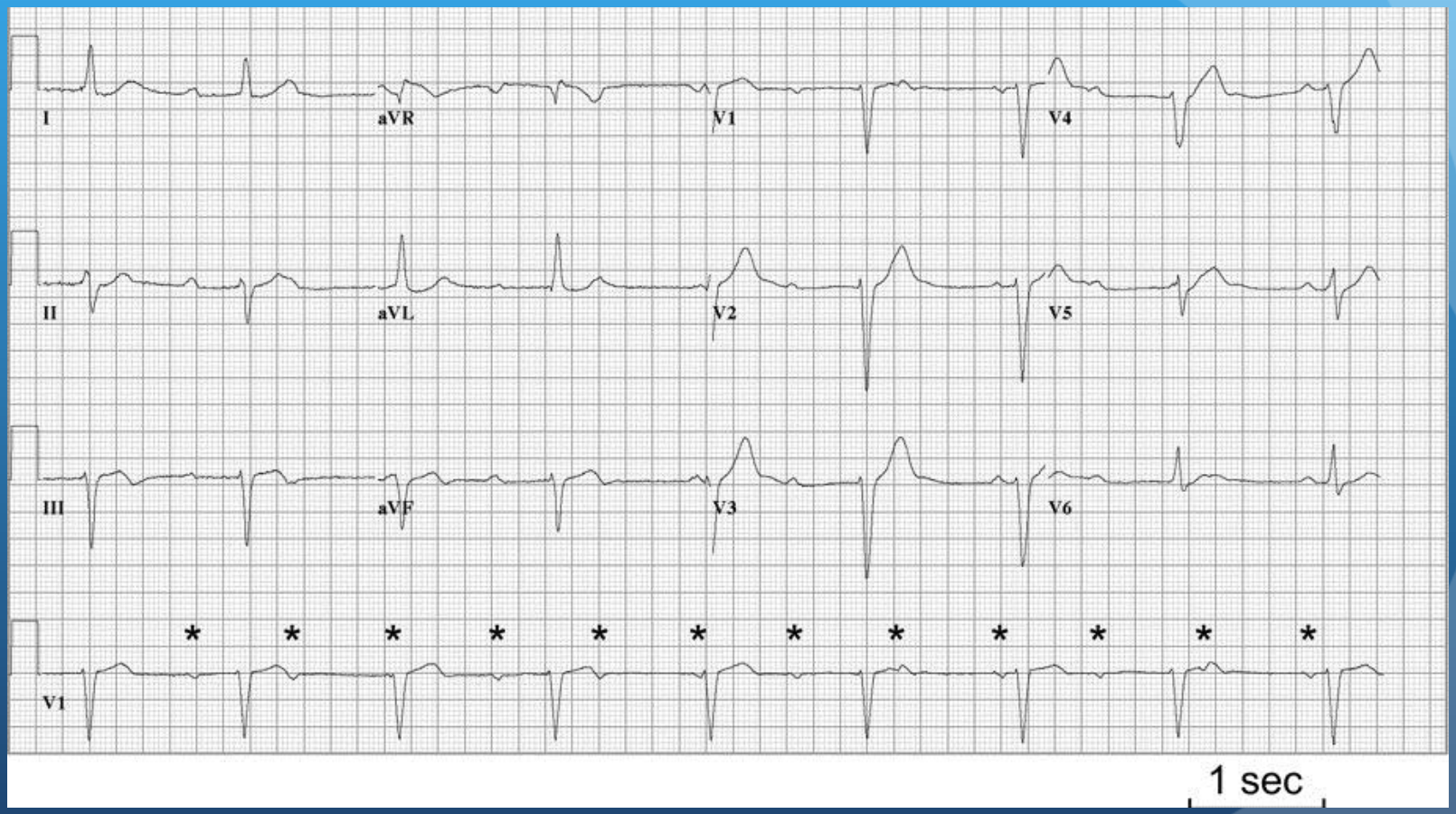

Case 5 (cont):

- The patient is found to have severe mitral stenosis on echocardiogram.
- It also turns out that the reason why she was on hemodialysis is that all vascular access options had been exhausted with previous AV fistulas on both upper extremities that have failed.

Venogram from left upper extremity

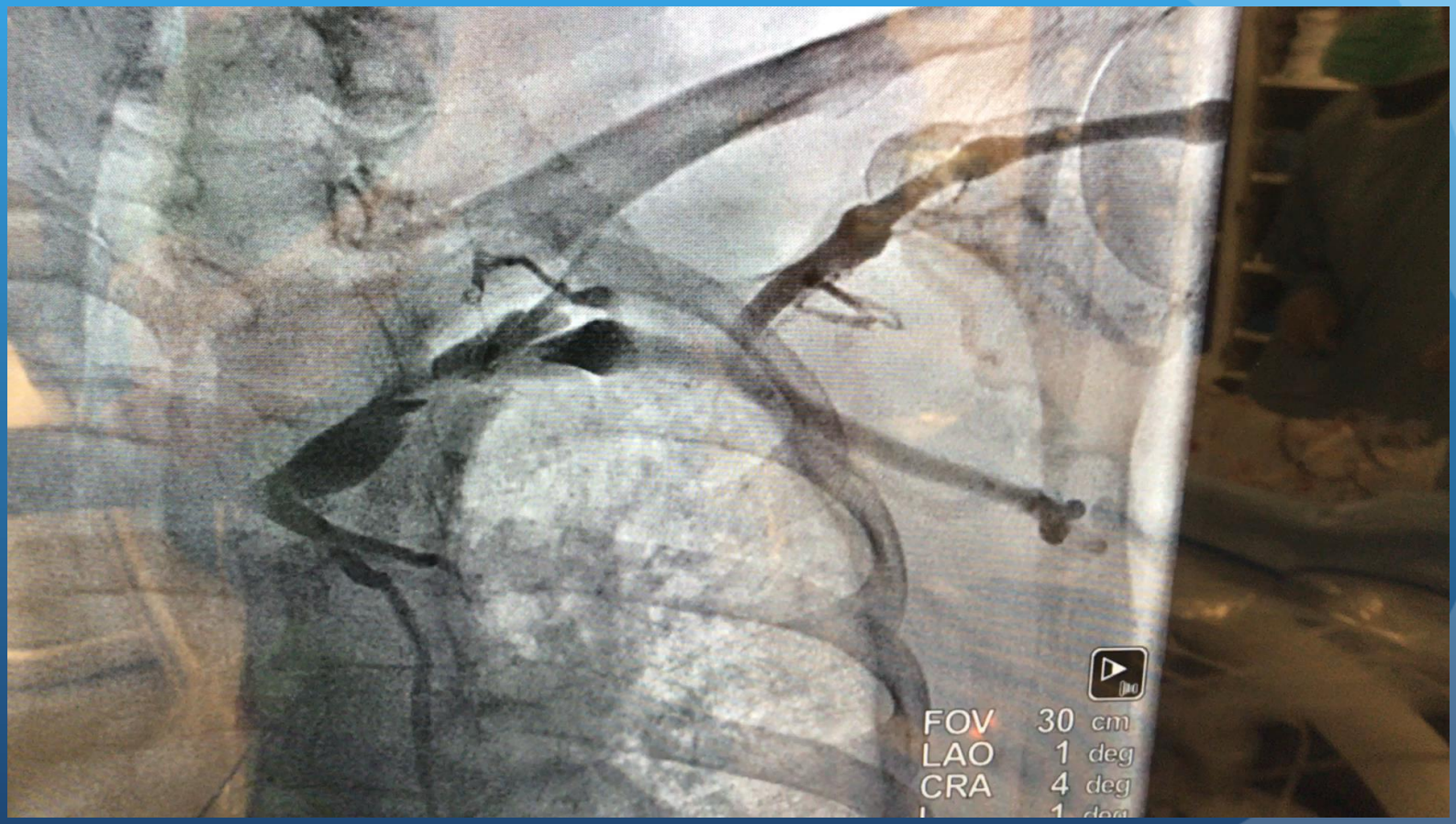

Leadless Pacemaker

- Combines all the components of a typical single chamber pacemaker into a capsule shaped device that is entirely implanted in the RV.

Leadless Pacemaker

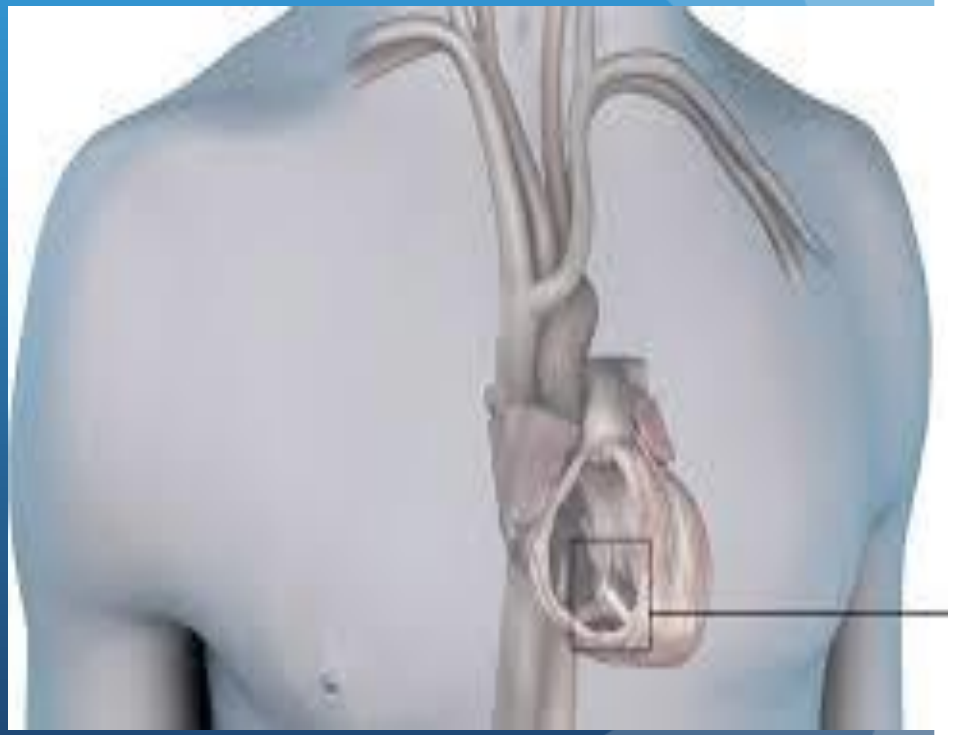

Leadless Pacemaker

- 99% implant success rate and extremely low dislodgement rate.
- Eliminates many of the complications associated with transvenous pacemakers – no pocket or lead-related complications
- Longevity is typically over 10 years!

Leadless Pacemaker

- Currently only indicated for patients who typically would only need a ventricular single chamber pacemaker:
  - Chronic afib with slow ventricular response.
  - Periodic bradycardia without the need for atrial pacing.

- Also indicated for patients with vascular access problems (typically hemodialysis patients) or high risk for pocket infection.

Case 5 (cont)

- Leadless pacemaker was implanted without difficulty.
- Patient has been evaluated by structural heart team and CT surgery at Mt. Carmel as well as Cleveland Clinic and is not felt to be a candidate for mitral valve replacement or intervention due to comorbidities.
- Was seen in clinic at the beginning of February and is clinically stable.


30 cm
117 cm
25 cm
1 deg
0 deg
6 deg

Case 6:

- 40 yo woman with no prior cardiac history presents with one month of constant fatigue and associated occassional lightheadedness. She denies syncope. ECG shows complete heart block.
- Extensive workup did not reveal any cause for her heart block (lyme neg, no evidence of infiltrative cardiomyopathy, lupus, etc.)
- Left ventricular ejection fraction is normal.

Case 6 (cont):

- What type of pacemaker should be implanted?
  - A) Dual chamber pacemaker
  - B) Biventricular pacemaker
  - C) Single chamber leadless pacemaker
  - D) Dual chamber pacemaker with RV lead in the position of the His bundle.

Dual chamber pacemaker for complete heart block

- Leads in the atrium and ventricle – replace the existing wiring system.
- RV lead paces the muscle of the right ventricle and spreads over muscle to activate the left ventricle. Creates a left bundle branch pattern on ECG and ventricular dyssynchrony.

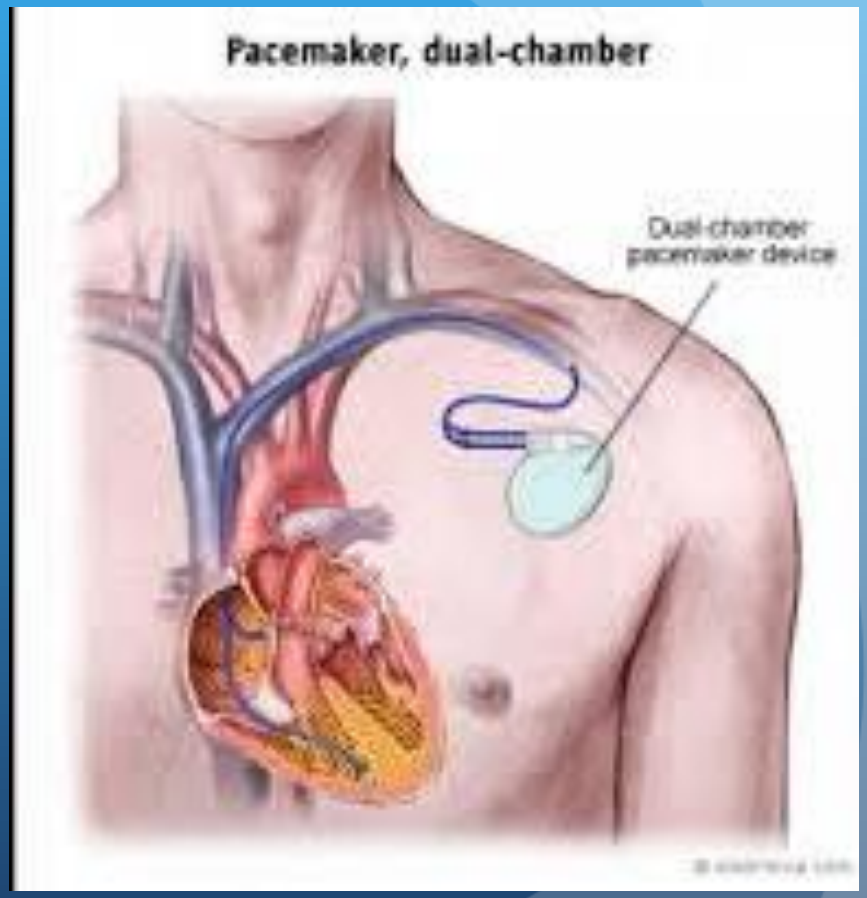

Pacemaker Mediated Cardiomyopathy

- Has been reported to develop in up to 20% of patients who undergo dual chamber pacemaker implant for complete heart block.
- Often requires upgrade of dual chamber system to biventricular pacemaker (lead in the coronary sinus).
- BLOCK HF trial in NEJM in April 2013 showed that patients with biv pacemakers implanted and LVEF <50% had less heart failure and death than patients who received dual chamber pacemakers.

Khurshid et al. Heart Rhythm. May 31, 2014

His Bundle Pacing

- Dual chamber pacemaker is implanted, but the RV lead is positioned on the His bundle.
- Pacing the His bundle results in a narrow complex QRS that is similar to the sinus rhythm QRS.
- The result is that there is normal activation of the ventricles and reduced risk of pacemaker mediated cardiomyopathy.

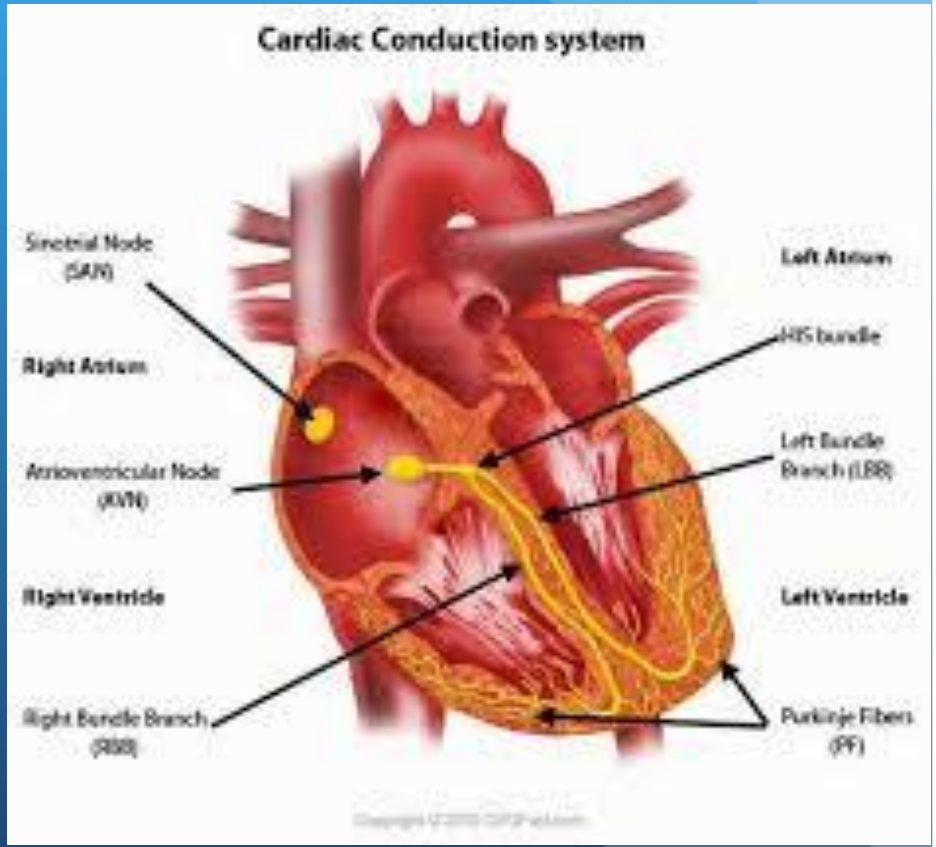

His bundle pacing (cont)

- There is a trend to implant more His bundle pacemakers, in particular in patients who will require frequent RV pacing.
- Procedure time is higher for the implant and there is a higher rate of lead dislodgement.
- Pacing thresholds are typically higher in this position, which drains the battery quicker.

Case 6 (cont.) – His bundle pacer implanted.

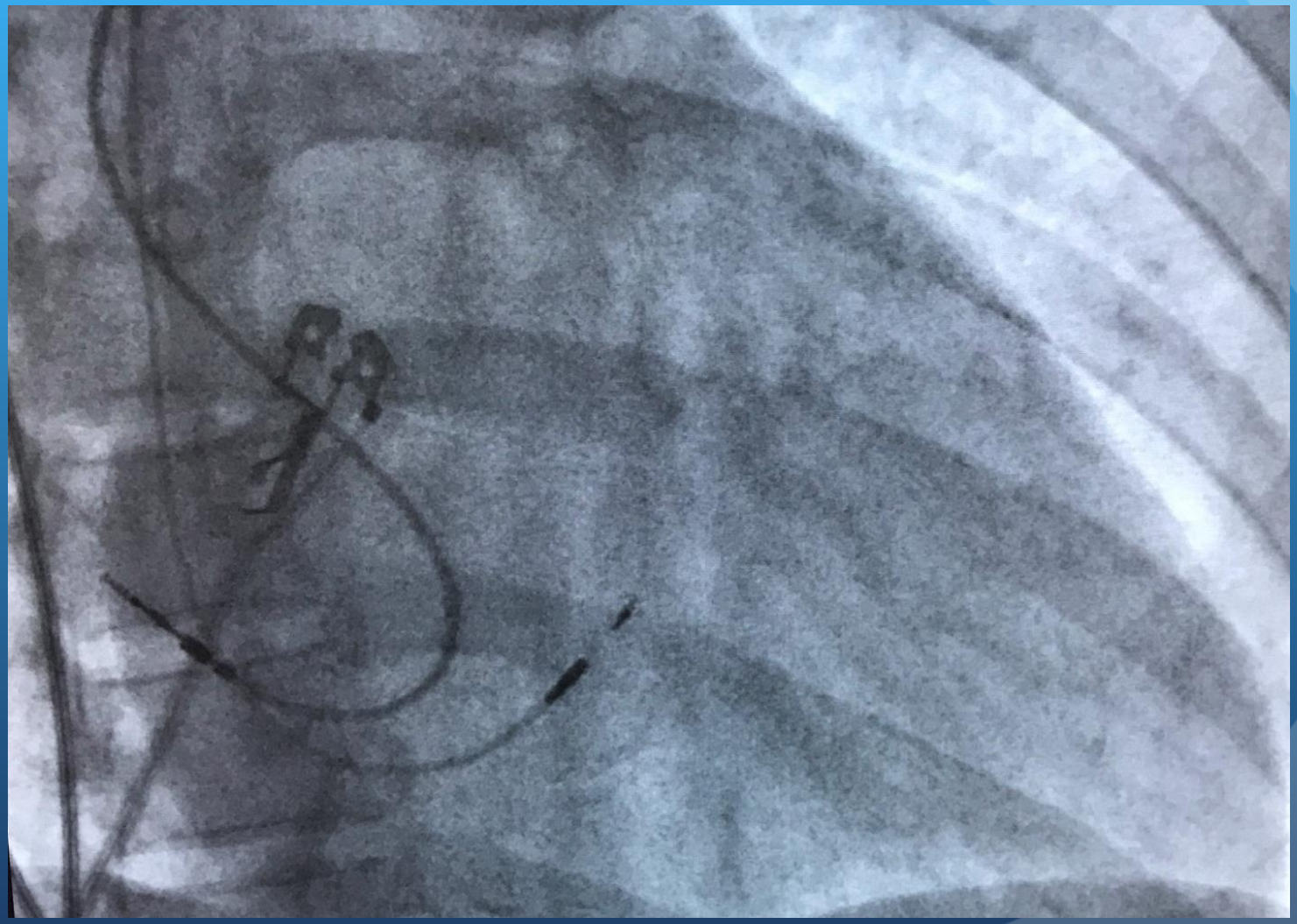

ECG – His Bundle Pacing

Case 7: Bleeding in patient with AF and high risk for stroke

- A 75 year old woman with history of hypertension, and diabetes was recently diagnosed with paroxysmal atrial fibrillation. She has had upper GI bleeding in the past with negative workup, including capsule endoscopy.
- What is the patient's CHADS VASC score?
  - A)2
  - B)3
  - C)4
  - D)5

CHADS2

- Risk score developed in 2001 based on the National Registry of Atrial Fibrillation (compiled from 7 states of Medicare participants).
  - **Congestive Heart Failure – 1 point**
  - **Hypertension – 1 point**
  - **Age ≥ 75 – 1 point**
  - **Diabetes – 1 point**
  - **Stroke – 2 points**

CHADS2

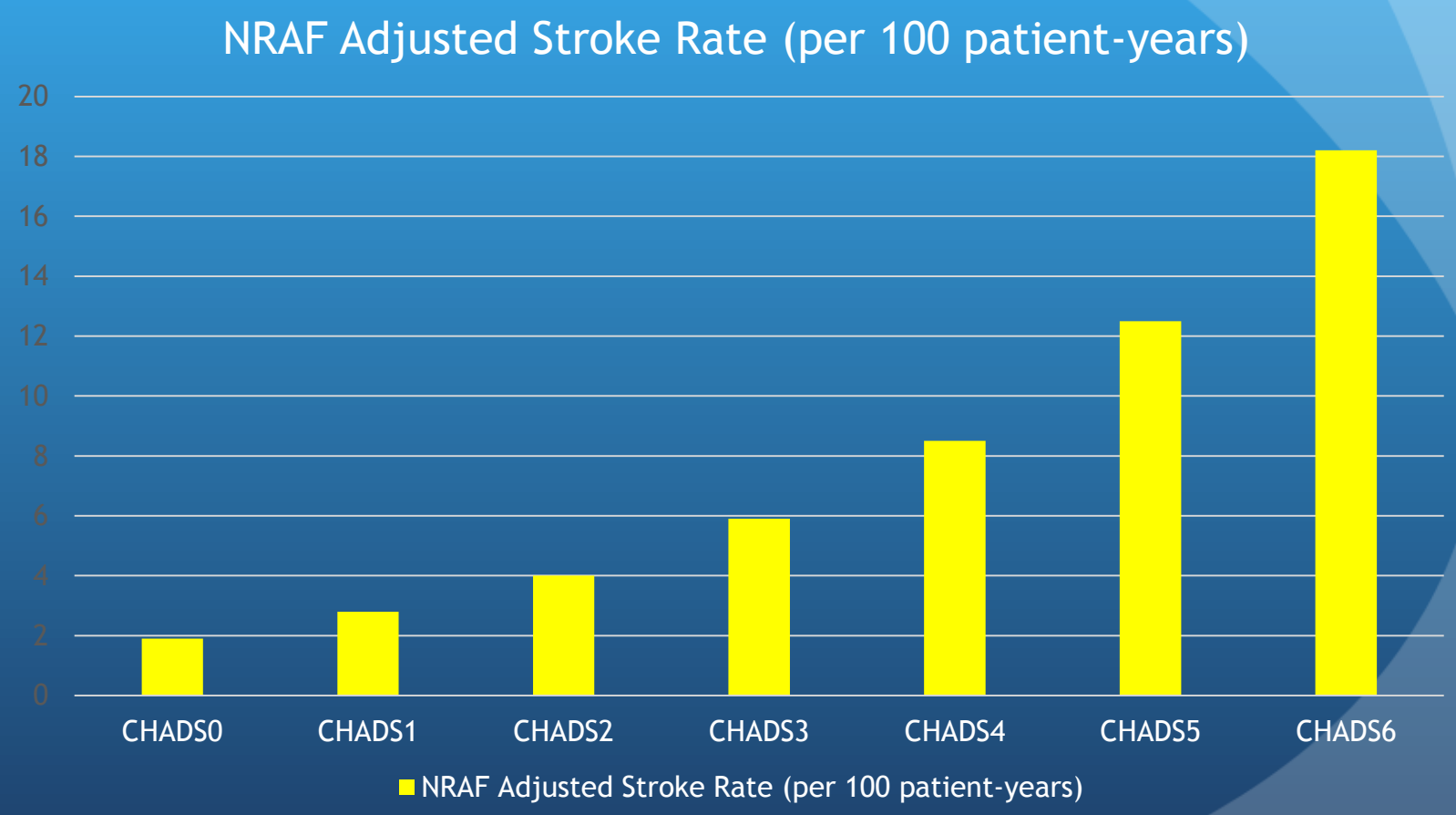

JAMA 2001;285(22):2864

CHA2DS2-VASc

- Adds more sensitivity to the CHADS2 scoring system
  - Congestive Heart failure – 1 point
  - Hypertension – 1 point
  - **Age ≥ 65 – 1 point**
  - **Age ≥ 75 – 2 points**
  - Diabetes – 1 point
  - Prior Stroke or TIA – 2 points
  - **Vascular disease (including h/o CAD) – 1 point**
  - **Female Sex – 1 point**

Validation Study Assessing the CHADS2 and CHA2DS2-VASc Scores in 90,490 patients without warfarin

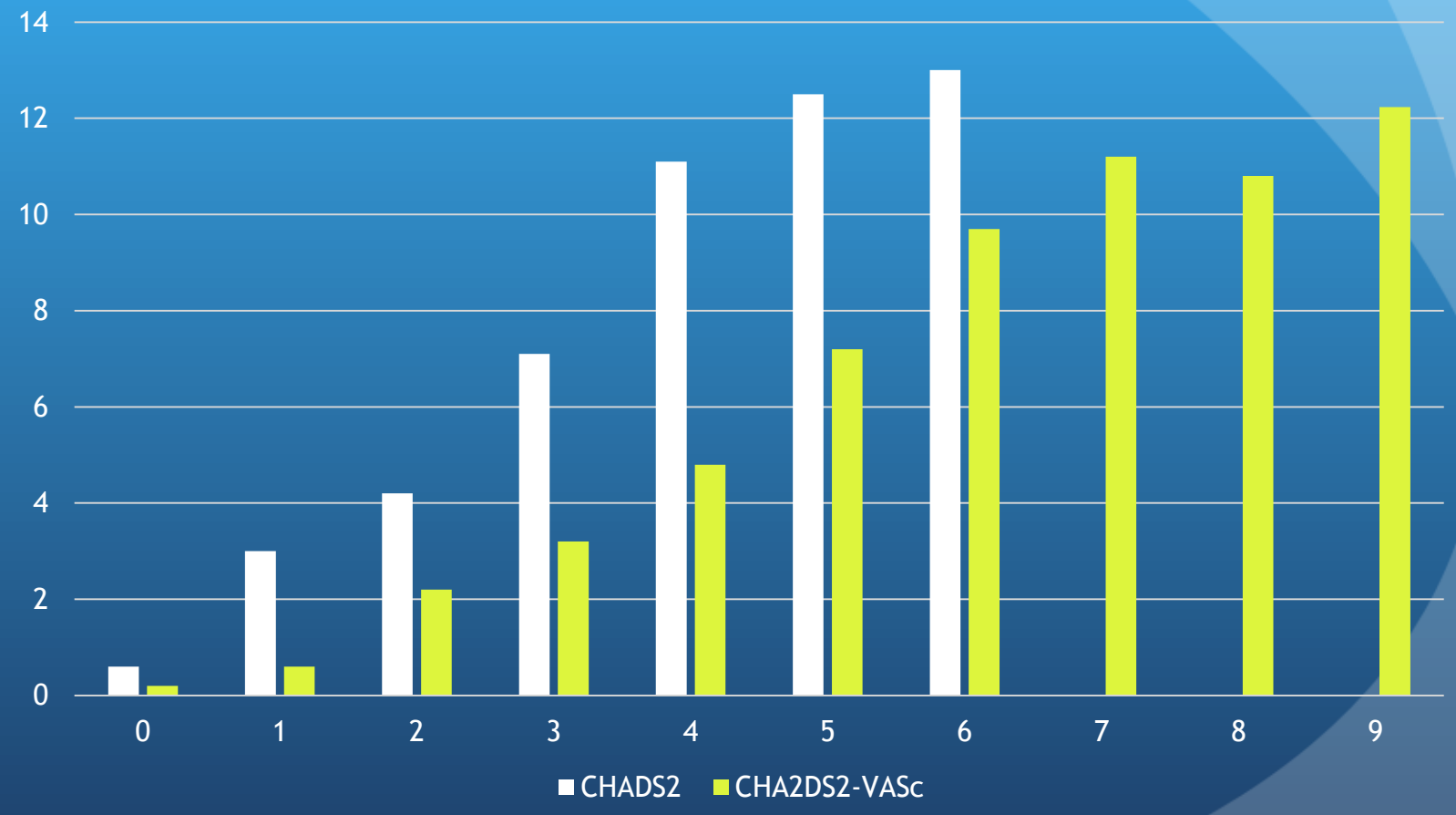

Eur Heart J 2012;33(12):1500-1510

Case 7 (cont.)

- Her CHADS VASC score is 5, putting her at high risk for thromboembolism.
- She is also at higher risk of recurrent GI bleeding.
- Let's say that you put her on apixaban 5mg po bid and she has another GI bleed.
- What would you do next?
  - A) Stop antiocoagulation and leave on Aspirin
  - B) Switch to coumadin
  - C) Switch to pradaxa
  - D) Refer for left atrial appendage occlusion

Watchman Left Atrial Appendage Occlusion

- Achieved noninferiority compared to coumadin for stroke or systemic embolism in the PREVAIL trial in 2014 and PROTECT AF trial in 2013.
- Requires anticoagulation for 45 days, then can be stopped.

Reddy et al. Circulation. 2013; 127; 720-729

Holmes et al. JACC Vol 64, issue 1, 8 Jul 2014

Watchman (cont)

- Approved by CMS for patients with CHADS VASC ≥ 3 who are deemed not to be candidates for long-term oral anticoagulation.

Any Questions?